
Diode Laser-Assisted Hair Removal in Asians: A Study of 101 Japanese Patients

Taro Kono, MD, Motohiro Nozaki, MD

Department of Plastic and Reconstructive Surgery

Tokyo Women's Medical University

Tokyo, JAPAN

BACKGROUND

During the past few years, a variety of laser systems for hair removal therapy have been developed and widely implemented worldwide. Skin types vary country to country according to geography and ethnicity, and these differences suggest that treatment parameters—if not laser wavelengths—should be selected based upon the unique factors of the patient population. Such factors include patient skin color, ethnic background, hair composition and diameter, and epidermal melanin content. Although Asian skin types and ethnicities are wide ranging, it is clear that hair color and epidermal melanin content are quite different in comparison to Caucasian based populations. In this retrospective study, we evaluated the efficacy and safety of a high-powered 800 nanometer diode laser on 101 Japanese patients.

Asian patients are ideal for laser assisted hair removal in the sense that their melanin-rich hair shafts act as strong absorbers of 700-900 nanometer light. Unfortunately, however, Asian populations also have a melanin-rich epidermis which greatly increases the possibility of untoward complications due to competing absorption by the epidermis of laser light intended to be absorbed by the hair shaft. Since it has been clearly documented that there is a strongly positive correlation between increasingly higher fluence and actual hair loss, laser hair removal is most effectively performed when the highest fluence that the skin can safely withstand is selected. As such, the ideal laser hair removal system for Asian skin is one wherein it

is possible to use high fluences while providing maximum epidermal protection.

Potential epidermal damage during laser hair removal can be minimized by using lower fluences (<20 Joules per cm²), but lower fluences diminish treatment effectiveness resulting in a higher regrowth rate and/or significantly higher treatment number. Rather than simply lowering fluence, a much more effective and efficacious way of protecting the melanin-rich epidermis without compromising treatment efficacy is through the employment of active skin cooling and longer pulsewidths (up to 30 milliseconds). Through the use of active skin cooling and longer pulse durations, it becomes possible to safely treat Asian skin at fluences that provide permanent hair reduction effects.

INTRODUCTION

Since April of 1998, we have owned and used the LightSheer™ diode based laser hair removal system (Coherent Medical, Santa Clara, California, U.S.A.) at our university hospital's outpatient department. As of March 2000, we have successfully treated 101 patients and report our results and experiences herein. In addition to treatment efficacy and complications, we evaluated the clinical effectiveness of the LightSheer's active skin cooling system and have reported those results separately. As of this writing, this is the first report of which the authors are aware regarding clinical experiences using the LightSheer on an all-Asian treatment population.

SUBJECTS AND METHODS

Patients

Between April 1998 to March 2000, 101 patients underwent laser hair removal therapy at our facility. Patients with photo-hypersensitivity, hemorrhagic tendencies, pregnancy, known malignant tumors, herpes simplex, or suntans were excluded. There were 28 men and 73 women with a median age of 30.3 years (range: 6 to 72 years). Treatment areas were elective, and were broken down as shown below in Table 1.

TABLE 1: TREATMENT AREAS

Area	Patients
Axillae	31
Head/Face	35
Arms	13
Legs	17
Bikini	5
TOTAL:	101

Laser system

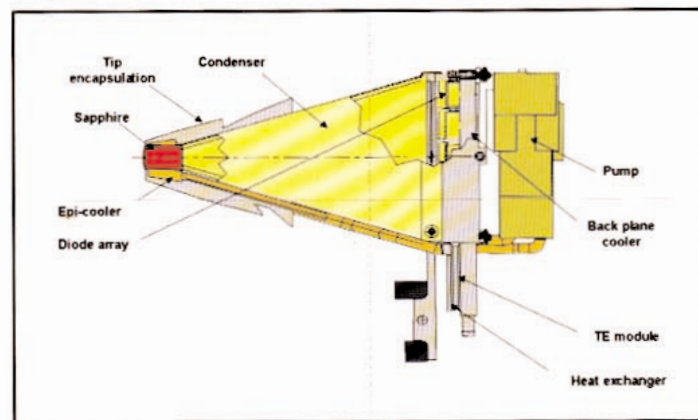
The LightSheer laser system employed has a wavelength of 800 nanometers, and has the characteristics shown below in Table 2. One of the most novel and interesting features of the system is the aforementioned contact cooling system ChillTip™ (Figure 1) which is described and discussed in greater detail below.

TABLE 2: LASER CHARACTERISTICS

Wavelength	800nm
Pulse duration	5-30 milliseconds*
Spot size	9x9 millimeters*
Fluence	10-40 Joules per cm ² *
Repetition rate	1 pulse per second*

*More recent models have enhanced capabilities

FIGURE 1: CHILLTIP™ HANDPIECE



Treatment method

As the absorbing target of laser hair removal is melanin within the hair shaft, it is essential that the hair shaft be present within the hair follicle at the time of treatment. As such, hair extraction through plucking and other depilatory methods including waxing was prohibited for 2 months prior to commencing treatments. As is typical with laser assisted hair removal, treatment sites were closely shaved immediately before laser irradiation in order to avoid epidermal damage. Anesthetics were typically not used as the procedure is well tolerated by most patients, but a 7% lidocaine emollient-based cream was used for patients averse to pain. Interestingly, several patients remarked that the cold sapphire tip of the treatment handpiece provided a comforting anesthetic-like effect which made treatments more tolerable.

A Japanese Skin Type (JST) classification system exists, but because most readers will be unfamiliar with it, equivalent Fitzpatrick Skin Types and corresponding treatment fluences and pulse settings are shown below in Table 3. Patients were grouped into like skin types based on a combination of observed skin characteristics, tanning question responses, and actual measured melanin content which was evaluated using a melanin measuring device (Mexameter MX-16, Courage+Khazaka Electronic GmbH, Germany).

TABLE 3:
SKIN TYPES, FLUENCE RANGES, PULSEWIDTHS

Skin Type (Fitzpatrick)	Fluence (Joules/cm²)	Pulsewidth
Type II	20-40	Auto, 30ms
Type III	18-40	Auto, 30ms
Type IV	18-35	Auto, 30ms

Pulsewidth selection was either the fixed 30 millisecond mode or the "Auto" mode. With the LightSheer in Auto mode, the pulsewidth is exactly one-half of the fluence setting in milliseconds. For example, 20 milliseconds when 40 Joules per cm² is selected, 15 milliseconds when 30 Joules per cm² is selected, etc. Test shots were performed in 2 Joule increments to assess the safety of increasingly higher fluences. In principle, the highest fluence tolerated by the patient without producing epidermal damage was selected.

Photographic records were taken before and immediately after laser treatments, but final assessments of effectiveness were made 6 months after the last treatment, and were evaluated visually by 2 plastic surgeons not involved in treating patients. Hair removal efficacy was graded according to perceived reduction as follows: 1 = 0-19%; 2 = 20-39%; 3 = 40-59%; 4 = 60-79%; 5 = 80-100%

CLINICAL RESULTS AND OBSERVATIONS

Efficacy

The average follow-up period after the last treatment averaged 9.4 months with a minimum of 6 months and a maximum of 22 months. Table 4 shows raw summary data from the 101 patients based on observed hair loss and treatment number. All of our initial experiences with the device are recorded—including control patients and test patients—and this accounts for the high number of patients receiving less than 3 treatments. Further, several children were treated for laser hair removal of hairy scalp tissue after having undergone microtia reconstructive surgery, and these cases typically required just 1 or 2 treatments for excellent results. Last, as all treatments were

elective and not part of a formal clinical trial, follow-up visits were not enforced.

These comments aside, trends noted in treating other ethnic groups were likewise noted in this study. Specifically, increasing hair loss with multiple treatments and a miniturization and concomitant color lightening of regrowing hairs. Also, corresponding to hair growth cycles, 6 treatments were necessary for satisfactory results in facial areas whereas good results in axillary and bikini line areas were achieved with as few as 3 or 4 treatments.

TABLE 4: RAW SUMMARY TREATMENT DATA

%Hair Loss	Treatment Count*						TOTAL PATIENTS
	1Tx	2Tx	3Tx	4Tx	5Tx	6Tx	
0-19%	5	1	0	0	0	0	6
20-39%	14	5	4	2	2	0	27
40-59%	2	10	1	2	1	2	18
60-79%	2	16	2	4	0	2	26
80-100%	3	3	9	2	6	1	24
TOTAL	26	35	16	10	9	5	101

*Number of patients receiving this Tx count

From the raw summary data in Table 4, a few general conclusions can be drawn (Table 5). First, all patients experienced temporary hair loss with even single treatments. Second, 50% of patients achieved greater than 60% hair reduction. We consider this especially significant given the fact that, due to the nature of the study, 76% of the patients had 3 or fewer treatments. In patients undergoing more typical treatment regimens ranging from 4-7 treatments, our on-going research shows that total hair reduction of greater than 80% is possible on a consistent basis in Japanese patients.

TABLE 5: TREATMENT CONCLUSIONS

1. Patients achieving temporary hair loss:	100%
2. Patients achieving >60% hair reduction:	50%
3. Patients undergoing 3 or fewer treatments:	76%

Case study 1: Microtial reconstructive surgery with laser hair removal

For children suffering from abnormally small ears, microtial reconstructive surgery uses scalp tissue to reconstruct a normal-sized ear. The surgical technique is highly effective, but patients suffer from hair growth from the donor scalp tissue. Laser hair removal provides an excellent therapy for such patients, and is extremely effective with just 1-2 treatments.

Figures 2 and 3 below dramatically show and illustrate the efficacy of laser hair removal effects on such tissue. Figure 2 is biopsied tissue magnified by a 20x video-microscope. Treated and non-treated tissue areas are clearly visible, and the treated tissue shows dramatic reduction in hair count and marked miniturization of the few regrowing hairs. Below the skin surface, note that the non-treated side shows several anagen phase hairs that have yet to break the surface, whereas the treated side shows that even these sub-surface hairs are significantly reduced in count.

FIGURE 2: BIOPSIED SKIN TISSUE

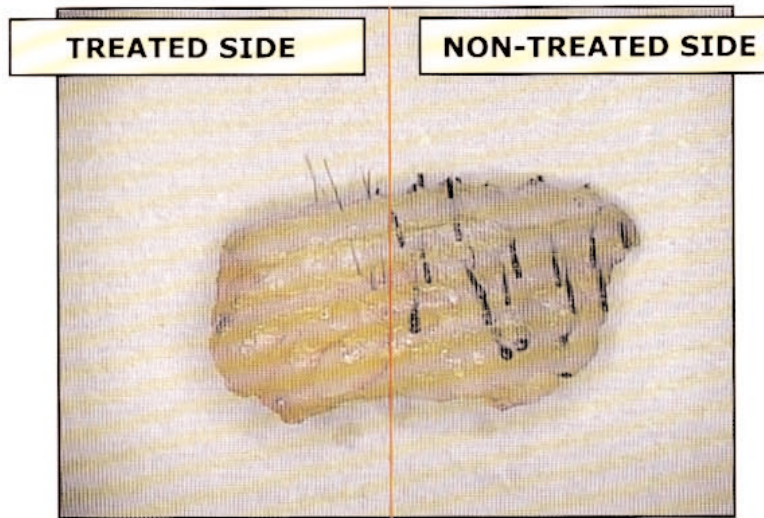
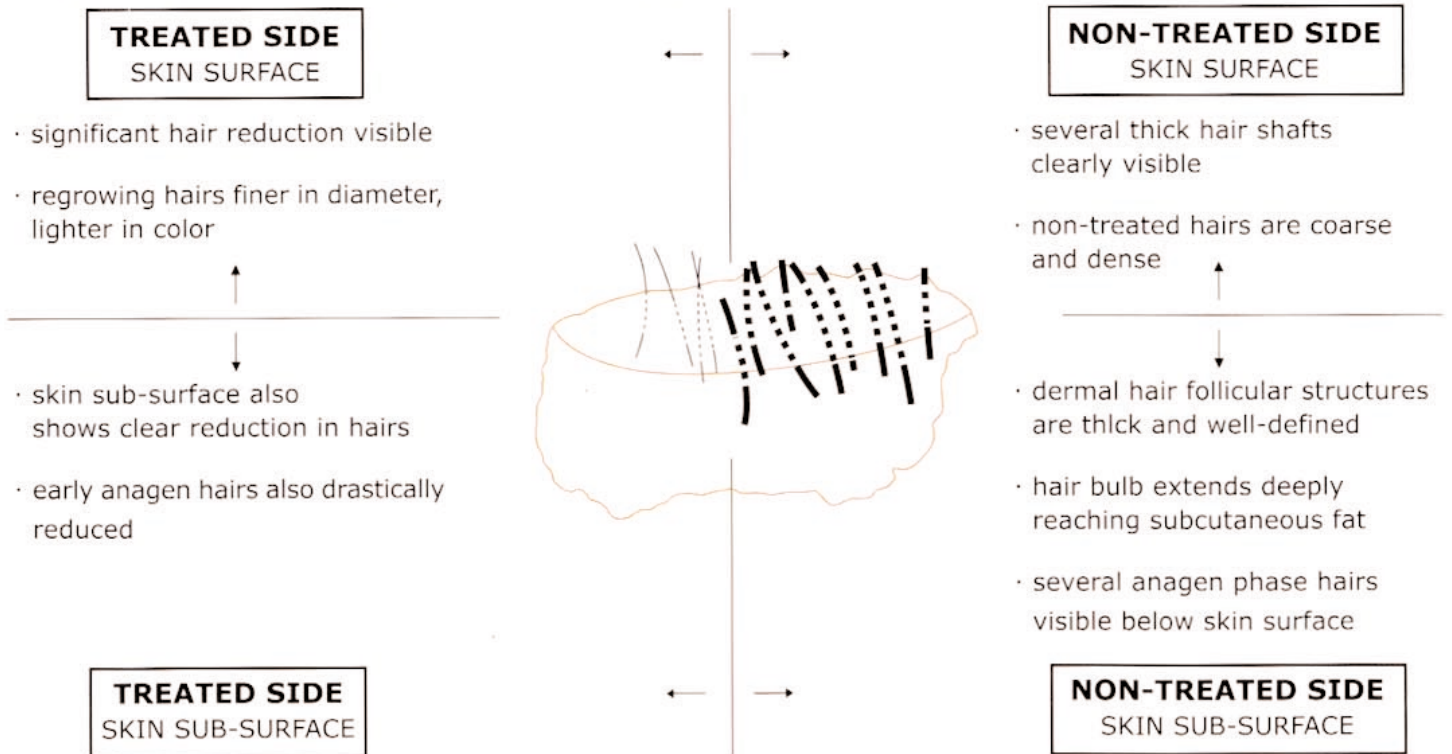


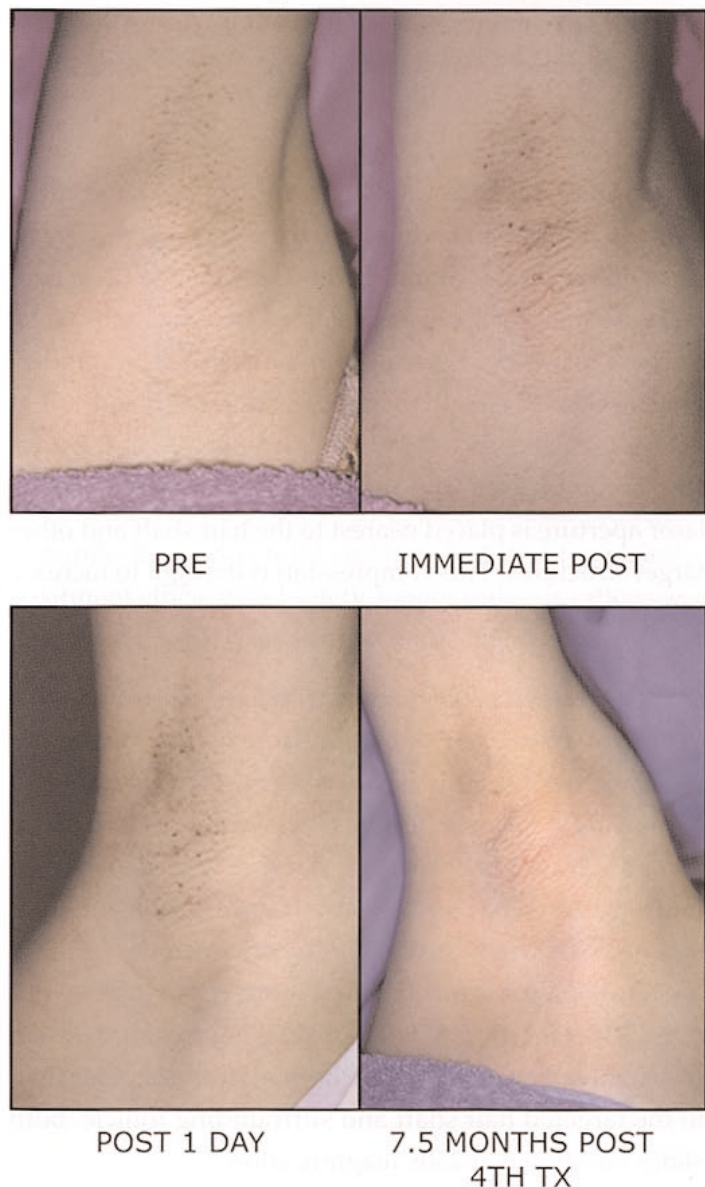
FIGURE 3: BIOPSIED SKIN TISSUE ILLUSTRATION



Case study 2: 34 year-old female axilla

Figures 4-7 below are of a 34 year-old female who underwent a total of 4 laser hair removal treatments of her axilla. Pre, immediately post irradiation, post irradiation 1 day, and 7.5 months after the 4th treatment are shown in order from left to right. In addition to excellent results of >90% hair reduction, this patient was safely treated at 40 Joules per cm² fluence. The combination of the long 800 nanometer wavelength and contact cooling before, during, and immediately post irradiation allows for highly effective and safe treatments to be performed on Asian skin.

FIGURES 4-7: 34 year-old female axilla, 40J



Complications

Complications were quite mild and all of a transient nature with no reported scarring or permanent events. Complications are summarized below in Table 6. Erythema, although not normally considered a “complication” of laser surgery, was recorded if it persisted for more than 2 days. 8 patients experienced such persistent erythema, and it occurred predominantly in darker skin types—2 cases of Fitzpatrick Type III, and 6 cases of Type IV—and also was most prevalent when treating male faces. Folliculitis was also observed in 8 cases with 7 incidences observed in male facial perioral treatments.

The overall incidence and degree of complications was low and mild, but it is clear that great care needs to be exercised when treating male beard hair. In addition to using lower fluences (beginning with test shots at 10 Joules per cm²), the longer pulse setting of 30 milliseconds is recommended to lower the possibility of bulk thermal damage—especially with thicker and denser beard hair. A combination of high hair density and thick hairs means that treated tissue can rise in temperature to ranges that can cause burn incidents which may lead to pigmentary changes or even scarring in severe cases. At present, our treatment technique for Type III and IV male facial hair patients is to treat at <18 Joules per cm² at the 30 millisecond pulse setting for initial treatments. After hair density has been reduced, we then gradually increase fluence for improved efficacy. Although very effective, male beard treatments with the LightSheer require patience, lower fluences, longer pulsewidths, and multiple treatments in comparison to other body areas.

TABLE 6: COMPLICATIONS

Complication Type	Patients
Persistent erythema (>2 days)	8
Folliculitis	8
Hyperpigmentation (transient)	2
Hypopigmentation (transient)	1
Blistering	1
Scarring	0
TOTAL:	20

DISCUSSION

The challenge for laser assisted hair removal in darker skinned populations is to deliver sufficiently high fluence to destroy the stem cells surrounding the hair follicle while protecting the melanin-rich epidermis from thermal damage. Longer pulse durations—especially those longer than the thermal relaxation time of the epidermis—provide some protection to the skin, but active cooling of the epidermis before, during, and after the laser pulse is critical for maximum safety.

It has been reported earlier that the ideal pulse duration for laser hair removal is 10-100 milliseconds. At these longer pulse durations, heat generated in the epidermis has time to dissipate through conduction to surrounding structures, thus avoiding acute thermal damage to the epidermis. In addition to epidermal protection, continued recent research in laser hair removal indicates that longer pulse durations up to and even greater than 100 milliseconds have the benefit of destroying the stem cells surrounding the follicle which are thought to be important in the germination of new hair growth. Recent theories explain that “thermal diffusion time”—the time needed for heat absorbed by the hair shaft to conduct to the stem cells surrounding the follicle—is in the range of 30-200 milliseconds. Consequently, longer pulse durations enhance epidermal protection while providing additional diffusion time to destroy targets far from the laser light-absorbing hair shaft.

Long pulse durations alone, however, are not sufficient to completely protect the skin—especially in darkly complected patients. Also, as regrowing hairs emerge thinner and lighter in color, higher fluences combined with shorter pulse durations may provide more ideal clinical results for later treatments. As epidermal damage is directly proportional to fluence and inversely proportional to pulse width, active skin cooling becomes a necessity for patient safety at all pulsewidths.


The LightSheer has a unique and patented skin cooling system built into the handpiece which cools the treatment area before, during, and immediately after each laser

pulse. Through a complex network of copper microchannels surrounding the sapphire lens in the distal end of the handpiece, water cooled to approximately 5° C is circulated so that the lens—which is put in contact with the skin—is constantly cooled. Unlike typical laser delivery systems that exit a final lens, travel through air, and then reach the skin, this “ChillTip” enables the user to press the cold sapphire lens directly to the treatment area. Through conduction effects due to direct contact with the skin, the cold sapphire lens removes heat from the epidermis thereby lowering its nominal temperature from approximately 30° C to 9-15°C. When the laser is fired, the subsequent rise in the skin temperature is not enough to create thermal damage because the ChillTip works to lower skin temperature prior to laser irradiation, and then continues to conduct heat out of the skin during and after each laser pulse. This process is called “active contact cooling.”

The application of the ChillTip to the skin cannot result in freezing of the skin because the tip is kept at 5° C. Treatment efficacy is not diminished by keeping the tip in contact with the skin for even sustained periods as the effectiveness of cooling is greatest to the depth of the epidermal basal layer (60-80 µm depth), but rapidly falls off at depths greater than 100-200 µm. Additionally, as the tip is firmly compressed into the skin prior to treatment, the laser aperture is placed nearest to the hair shaft and other target structures. This compression is thought to increase treatment efficacy.


In earlier research, we demonstrated the effectiveness of skin protection that the ChillTip provides through a videomicroscope study wherein laser pulses were applied to patients at various fluence levels with the ChillTip on and off. Figure 8 below shows that skin treated at even 20 Joules per cm² shows coagulative degeneration and thermal necrosis when the ChillTip is off. With the ChillTip on, however, the same patient (Figure 9) can safely withstand 30 Joules per cm² without showing any kind of skin coagulative degeneration or thermal necrosis other than to the targeted hair shaft and surrounding follicle. Both slides are shown at 250x magnification.

FIGURE 8: 20J, CHILLTIP OFF



Thermal necrosis and coagulative degeneration of skin clearly visible

FIGURE 9: 30J, CHILLTIP ON



No thermal necrosis of skin surrounding follicle and hair shaft

CONCLUSION

In this retrospective study of 101 Japanese patients, we were able to achieve temporary hair removal in all patients with even single laser treatments. Longer lasting results required multiple treatments, and 50% of all patients achieved 60% or greater permanent hair reduction. Complications were mild and transient, and to maximize treatment efficacy and safety, longer pulse durations and active skin cooling are critical for darkly complected patient populations.

These initial experiences with the LightSheer on an all-Japanese patient base demonstrated that 800 nanometer diode laser assisted hair removal can be performed as effectively and as safely on Asian patients as on Caucasian patients.

REFERENCES

- 1) Adrian RM and Tanghetti E. Clinical Evaluation of a High Energy Long-Pulse Ruby Laser for the Treatment of Unwanted Body Hair. *Lasers Surg Med*; 9(36), 1997.
- 2) Altshuler GB, Zenzie HH, Erofeev AV, Smirnov MZ, Anderson RR, Dierickx CC. Contact cooling of the skin. *Physics in Medicine & Biology*; 44(4):1003-23, 1999 Apr.
- 3) Anderson RR, Parish JA. Selective photothermolysis: precise microsurgery by selective absorption of pulsed radiation. *Science*; 220:524-527, 1983.
- 4) Chui CT, Berger TG, Price VH, Zachary CB. Recalcitrant scarring follicular disorders treated by laser-assisted hair removal: a preliminary report. *Dermatol Surg*; 25(1):34-7, 1999.
- 5) DiBernardo BE, Perez J, Usal H, Thompson R, Ferraro FJ, Fallek SR. Laser hair removal. *Clin Plast Surg*; 2000 Apr;27(2):199-211.
- 6) Dierickx CC, Grossman MC, Farinelli WA, Anderson RR. Permanent hair removal by normal-mode ruby laser [see comments]. *Archives of Dermatology*; 134(7):837-42, 1998.
- 7) Garcia C, Alamoudi H, Nakib M, Zimmo S. Alexandrite Laser Hair Removal is Safe for Fitzpatrick Skin Types IV-VI. *Dermatol Surg*; 2000 Feb;26(2):130-134.
- 8) Gault DT, Grobbelaar AO, Grover R, Liew SH, Philp B, Clement RM, Kiernan MN. The removal of unwanted hair using a ruby laser. *Br J Plast Surg*; 1999 Apr;52(3):173-7.
- 9) Gold MH, Bell MW, Foster TD, Street S. Long-term epilation using the EpiLight broad band, intense pulsed light hair removal system. *Dermatol Surg*; 23(10):909-13, 1997.
- 10) Goldberg DJ, Littler CM, Wheeland RG. Topical suspension-assisted Q-switched Nd:YAG laser hair removal. *Dermatol Surg*; 23(9):741-5, 1997.
- 11) Goldberg DJ, Ahkami R. Evaluation comparing multiple treatments with a 2-msec and 10-msec alexandrite laser for hair removal. *Lasers Surg Med*; 1999;25(3):223-8.
- 12) Goldberg DJ, Samady JA. Evaluation of a Long-Pulse Q-Switched Nd:YAG Laser for Hair Removal. *Dermatol Surg*; 2000 Feb;26(2):109-113.
- 13) Grossman MC, Dierickx CC, Farinelli W, Flotte T, Anderson RR. Damage to hair follicles by normal-mode ruby laser pulses. *Journal of the American Academy of Dermatology*; 35(6):889-94, 1996.
- 14) Hasan AT, Eaglstein W, Pardo RJ. Solar-induced postinflammatory hyperpigmentation after laser hair removal. *Dermatol Surg*; 25(2):113-5, 1999.
- 15) 河野 太郎、野崎 幹弘：半導体脱毛レーザーにおける皮膚冷却装置 (Chill Tip®) の有用性の検討—ビデオマイクロスコープによる表皮損傷の観察—。日本レーザー医学会誌, 20 No.2 : 121 ~ 127, 2000.
- 16) Liew SH, Grobbelaar A, Gault D, Sanders R, Green C, Linge C. Hair removal using the ruby laser: clinical efficacy in Fitzpatrick skin types I-V and histological changes in epidermal melanocytes. *Br J Dermatol*; 1999 Jun;140(6):1105-9.
- 17) Liew SH, Ladhani K, Grobbelaar AO, Gault DT, Sanders R, Green CJ, Linge C. Ruby laser-assisted hair removal success in relation to anatomic factors and melanin content of hair follicles. *Plastic & Reconstructive Surgery*; 103(6):1736-43, 1999.
- 18) Lin TY, Manuskiatti W, Dierickx CC, Farinelli WA, Fisher ME, Flotte T, Baden HP, Anderson RR. Hair growth cycle affects hair follicle destruction by ruby laser pulses. *Journal of Investigative Dermatology*; 111(1):107-13, 1998.
- 19) Lou WW, Quintana AT, Geronemus RG, Grossman MC. Prospective study of hair reduction by diode laser (800 nm) with long-term follow-up. *Dermatol Surg*; 2000 May;26(5):428-32.
- 20) McCoy S, Evans A, James C. Histological study of hair follicles treated with a 3-msec pulsed ruby laser. *Lasers Surg Med*; 24(2):142-50, 1999. 21) McDaniel DH, Lord J, Ash K, Newman J, Zukowski M. Laser Hair Removal: A Review and Report on the Use of the Long-Pulsed Alexandrite Laser for Hair Reduction of the Upper Lip, Leg, Back, and Bikini Region. *Dermatol Surg*; 1999 Jun;25(6):425-430.
- 22) Nanni CA, Alster TS. Optimizing treatment parameters for hair removal using a topical carbon-based solution and 1064-nm Q-switched neodymium:YAG laser energy. *Archives of Dermatology*; 133(12):1546-9, 1997.
- 23) Nanni CA, Alster TS. Long-pulsed alexandrite laser-assisted hair removal at 5, 10, and 20 millisecond pulse durations. *Lasers Surg Med*; 1999;24(5):332-7.
- 24) Nanni CA, Alster TS. Laser-assisted hair removal: side effects of Q-switched Nd:YAG, long-pulsed ruby, and alexandrite lasers. *Journal of the American Academy of Dermatology*; 41(2 Pt 1):165-71, 1999.
- 25) Weiss G, Cohen B. The efficacy of long-term epilation of unwanted hair by noncoherent filtered flashlamp. *Lasers Surg Med*; 2000;26(4):345.
- 26) Wimmershoff MB, Scherer K, Lorenz S, Landthaler M, Hohenleutner U. Hair Removal Using a 5-msec Long-Pulsed Ruby Laser. *Dermatol Surg*; 2000 Mar;26(3):205-210.



Enhancing Life. Advancing Technology.

Lumenis Inc.
2400 Condensa Street
Santa Clara, CA 95051 USA
Tel 408 764 3000
800 635 1313
Fax 408 764 3999
800 505 1133
internet: www.lumenis.com
email: information@lumenis.com

Lumenis, its logo, LightSheer, and ChillTip are trademarks or registered trademarks of the Lumenis Group of Companies. Copyright © 2002 the Lumenis Group of Companies. All rights reserved.

Federal law restricts this device to sale by or on the order of a physician. Product specifications are subject to change without notice.

Printed in the U.S.A.

A1038-0900-5M