

Results of fractional ablative facial skin resurfacing with the erbium:yttrium-aluminium-garnet laser 1 week and 2 months after one single treatment in 30 patients

Mario A. Trelles · Serge Mordon · Mariano Velez ·
Fernando Urdiales · Jean Luc Levy

Received: 13 December 2007 / Accepted: 17 January 2008
© Springer-Verlag London Limited 2008

Abstract The erbium:yttrium-aluminium-garnet (Er:YAG) laser has recently been used in the fractional resurfacing of photo-aged skin. Our study evaluated the results after one single session of fractional resurfacing with Er:YAG. Thirty women participated in the study, with an average age of 46 years, skin types from II to IV, and wrinkle grades I to III. The 2,940 nm Er:YAG system used (Pixel, Alma Laser, Israel) had variable pulse durations (1 ms to 2 ms) and energy densities (800 mJ/cm² to 1,400 mJ/cm²) which, together with the number of passes (four to eight), were selected as a function of wrinkle severity. All patients received only one treatment. Postoperative side effects were evaluated. The number of wrinkles was documented with clinical photography and was scored. Histological assessment was carried out on two patients before and 2 months after treatment. All patients completed the study. Of the patients, 93% reported good or very good improvement of the degree of their wrinkles, with a satisfaction index of 83%. Pain was not a problem during treatment, and there

were no side effects except for in one phototype IV patient, who had hyperpigmentation. Histology 2 months after the single treatment demonstrated younger morphology of both the epidermis and dermis, with improvement of the pre-treatment typical elastotic appearance. At the parameters used in our study, only one treatment session of Er:YAG laser could achieve effective skin rejuvenation, with effects recognized in both the dermis and, more importantly, the epidermis. This regimen offers an interesting alternative to the conventional approach of multi-session fractional resurfacing.

Keywords Laser surgery · Fractional resurfacing · Er:YAG laser · Skin · Histology

Introduction

Laser ablative resurfacing remains the “gold standard” for rejuvenating severely photo-damaged facial skin, but it is associated with long-term sequelae-related patient downtime. Recently, fractional resurfacing has been introduced in the armamentarium of the dermatologist’s equipment. Fractional resurfacing employs a unique mechanism of action that repairs a fraction of skin at a time. The laser is used to resurface the epidermis and, at the same time, to heat the dermis to promote safely the formation of new collagen. The untreated healthy skin remains intact and actually aids the repair process, promoting rapid healing with only a day or two of downtime. Various modalities of “fractional” resurfacing have been offered as alternatives to laser ablative resurfacing, designed to decrease the photo-thermal side effects while still achieving good results, with faster healing of the skin and significant reductions in downtime [1].

M. A. Trelles · M. Velez
Instituto Medico Vilafortuny, Fundacion Antoni de Gimbernat,
Cambrils, Spain

S. Mordon (✉)
INSERM U703, IFR 114, Pavillon Vancostenobel,
Lille University Hospital, CH&U,
59037 Lille, France
e-mail: mordon@lille.inserm.fr

F. Urdiales
Instituto Médico Miramar,
Málaga, Spain

J. L. Levy
Centre Laser Dermatologique,
Marseille, France

Irrespective of the laser wavelength used in the fractional system, the primary target is both the epidermis and the dermis, with the aim of creating small zones of “micro-damage” separated by zones of unirradiated tissue that assist with the rapid healing process. The aim of the fractional approach is to obtain the best possible results with the least possible damage, and the degree of thermal damage delivered to the target skin depends on the dosage, the pulse width of the beam, and the number of passes over the same target area. A fractional system based on the erbium:yttrium-aluminium-garnet (Er:YAG) laser has recently become commercially available. When the Er:YAG laser is used for resurfacing in the fractional mode, recovery time is considerably shortened and traditional post-resurfacing sequelae are absent. Consequently, this allows patients a rapid return to their social or work environments. Debate continues on the use of multiple treatment sessions or one single treatment session. From our study we present the results obtained from 30 patients and the associated symptoms observed after a single session of fractional resurfacing by multi-pass Er:YAG laser.

Materials and methods

Patients and treatment

Thirty women participated in the study, with ages ranging from 25 years to 52 years (mean age 46 years). Three patients underwent full face resurfacing, eight, periocular and 19, upper lip. Four patients were skin phototype II; 18, type III and eight, type IV. Fifteen patients presented with degree III wrinkles, 11 degree II, and four degree I (Table 1). Tables 2 and 3 show the wrinkle grade broken down by the area to be treated and the fractional ablative resurfacing pulse programme chosen.

For inclusion in the study, patients were limited to those with wrinkles between degrees I and III, based on the Glogau scale. Type I wrinkles were defined as fine, seen with motion in association with mild elastosis, fine textural changes and a subtle accent of skin lines. Type II wrinkles were defined as a moderate number of fine wrinkles at rest, plus moderate-to-deep wrinkles with motion in association

Table 1 Patients (total=30) broken down by age group, skin phototype and wrinkle grade (Glogau scale). Grade III wrinkles were treated with the long pulse programme and grade II and grade I wrinkles were treated with the medium and short pulse programmes, respectively

Age group			Skin type			Wrinkle grade		
25-32 years	33-34 years	45-52 years	II	III	IV	I	II	III
7	8	15	4	18	8	4	11	15

with moderate elastosis (visible translucent yellow papules under direct lighting) and some dyschromia. Type III wrinkles were defined as a large number of fine-to-moderately deep wrinkles at rest, and very deep wrinkles with motion in association with severe elastosis and thickened yellow multipapular skin under direct lighting, coarse on palpation and with a significant number of dyschromic lesions.

Exclusion criteria for treatment included pregnancy, nursing, inflammatory skin diseases, open wounds, active herpes simplex, facial congenital/acquired naevi, and refusal to give signed informed consent.

Treatment details were explained to each patient, and all signed a form of informed consent for surgery and the use of clinical photography. The study was approved by the Antoni de Gimbernat Foundation Ethics Committee.

The laser used was the Pixel Er:YAG system (Harmony platform, Alma Laser, Israel) equipped with a beam splitter to divide the 2,940 nm beam into several sets of microbeams. The window of the laser handpiece was 11 mm×11 mm, supporting 49 microbeams. The system has three programmes for treatment pulse width: short (1 ms pulse width), medium (1.5 ms) and long (2 ms).

The energy programme for fractional resurfacing with this fractional Er:YAG laser is based on a variable pulse width at a fixed output power. Depending on selection of the short, medium or long pulse setting, the radiant exposures over the entire 11 mm×11 mm treatment area are 800 mJ/cm², 1,000 mJ/cm² and 1,400 mJ/cm², respectively. The manufacturer’s recommendation is that treatment can be given without the use of anaesthesia for all programmes, but, in clinical practice, repeated passes with the system with small inter-shot intervals over the same area inevitably leads to heat accumulation, especially when the long pulse option (1,400 mJ/cm²) is chosen, and, as a consequence, some degree of pain will be experienced, directly correlated with the number of laser passes. In our study, application of the long pulse setting for type III wrinkles was preceded by the administration of local anaesthesia (4% lidocaine in suspension, Laboratorios Profarplan, Barcelona, Spain) applied topically 2 h prior to surgery. The excess anaesthetic was removed and the skin surface cleaned. The

Table 2 Patients broken down by area treated and wrinkle grade. The upper lip accounted for the largest number of patients with grade III wrinkles in 50% of all patients

No. of patients	Area treated	Wrinkle grade		
		I	II	III
3	Full face	1	1	1
8	Periocular	2	2	4
19	Upper lip	2	7	10

Table 3 Results correlated with wrinkle site and grade and pulse programme as evaluated by patients at the 2-month assessment point

Wrinkles		Pulse programme	Results				
Site	Grade (n)		+++	++	+	±	-
Upper lip	I (2)	Short	1	1	0	0	0
	II (7)	Medium	1	4	2	0	0
	III (10)	Long	3	6	0	0	1
Periocular	I (2)	Short	0	2	0	0	0
	II (2)	Medium	0	1	1	0	0
	III (4)	Long	0	2	2	0	0
Full face	I (1)	Short	1	0	0	0	0
	II (1)	Medium	0	1	0	0	0
	III (1)	Long	0	1	0	0	0

+++ Very much less, ++ much less, + somewhat less, ± little or no improvement, - worse

laser was fired eight times, maintaining the head over the same area but turning it slightly around its perpendicular axis each time. Consequently, this technique corresponded to eight passes. Once the laser had been fired eight times, the handpiece was moved to another treatment area. In patients with types I or II wrinkles, where lighter fractional resurfacing was required, no anaesthesia was used and the programme was set to the short pulse mode (800 mJ/cm²) with four passes, or medium pulse mode (1,000 mJ/cm²) with six passes, respectively (Table 2) depending on the severity of the wrinkles. All patients, regardless of the degree of wrinkles, received only one treatment.

Standardized digital photographs (Sony MAVICA MVC-FD91) were taken of the patients' skin condition before the treatment (baseline assessment) and then 7 days and 2 months after treatment (7-day and 2-month assessments), maintaining uniformity in the patient's position, the lighting and the camera set-up. A separate floppy disk was kept for each patient to enable accurate repetition of the photography and follow-up. The clinical photography allowed comparative assessment of the state of lines, wrinkles and skin condition over the three assessment points. Following the fractional resurfacing, flupametasone gentamicin ointment (Flutenal Gentamicina, Lab. Recordati España, S.L., Madrid, Spain) was gently applied to the treated area. No occlusive dressing was used. Patients were recommended to use the ointment three times a day in small amounts (as a moisturizer), until spontaneous detachment of the scab that would form on the treated areas. No oral medication was prescribed, but patients were advised to take paracetamol, 500 mg every 4 h, if pain occurred.

Assessments

Patients were asked to return 24 h after treatment for control, and 7 days and 2 months after treatment for evaluation. All

patients were advised to begin their normal regimen of skin care and creams following the spontaneous detachment of the scab. Advice was also given regarding the avoidance of solar exposure, and the use of a UVA/B sun block with a solar protection factor 60 (SPF 60) was recommended.

Two patients from each of the three pulse width groups, as a trial population cross-section, volunteered to have 0.5 mm punch biopsies taken from the treatment area before and 2 months after treatment. Clinical photography ensured that the same biopsy point was not used more than once.

Patients were asked to record information regarding procedure-related pain and other postoperative side effects such as erythema and hyperpigmentation. Patients were instructed on how to score procedure-related pain using an 11-point visual analogue scale (VAS), where 10 was unbearable pain and zero was no pain, and the results were graded as follows: extremely painful (10–9 on the VAS, +++); very painful (7–8, ++); bearable pain (6–4, +); little pain (1–3, ±); and no pain (0, -) Answers were tabulated. At the 7-day and 2-month points the patients subjectively assessed erythema and hyperpigmentation (severe, +++; bad, ++; noticeable, +; mild, ±; and none, -); changes in their lines and wrinkles (very much less, +++; much less, ++; somewhat less, +; little or no change, ±; and worse, -); and the overall treatment efficacy based on the result as a whole (excellent, +++; good, ++; fair, +; little or no change, ±; and worse, -). The patients' satisfaction at the 2-month assessment, based on the improvement in lines, wrinkles and general skin condition, was graded as very satisfied (VS); satisfied (S); somewhat satisfied (FS); and not satisfied (NS). The values scored for VS and S were summed and expressed as a percentage to give the patient satisfaction index (SI). The efficacy of Er:YAG fractional resurfacing for skin rejuvenation was assessed objectively from the clinical photography at baseline, 7 days, and 2 months after treatment, by two independent expert and blinded aesthetic dermatologists. Where their assessment dramatically differed, consensus was reached after discussion. Grading was as follows: excellent improvement, +++ (85–100%); good improvement, ++ (60–84%); fair improvement, + (30–59%); little or no improvement, ± (0–29%); and worse, -.

The histological specimens taken at baseline and at the 2-month assessment were stained with haematoxylin and eosin (H&E), and an independent and blinded pathologist was asked to comment on any changes seen in the epidermal and dermal architecture.

Results

All patients completed the trial and participated in the two assessments. During Er:YAG fractional resurfacing, all patients treated with the long pulse programme reported

increased discomfort with some pain with the eight laser passes, despite the application of the topical local anaesthetic. In particular, pain was experienced from the fifth pass onwards and when the treatment was for the full face. However, no patient refused to finish the treatment. On the other hand, all patients treated with the short and medium pulse programmes also experienced some discomfort with noticeable pain, but again no patient refused to continue with the treatment.

One day after surgery patients treated with the short and medium pulse programmes presented with skin irritation. Some erythema was present, with slight scabbing that spontaneously detached after approximately 4 or 5 days, sooner than was the case following treatment with the long pulse programme. Once the skin was free of the small fine scab in all treatment groups, erythema was more apparent, but the reaction was much less than when compared with standard ablative laser resurfacing, according to the opinion given by the clinical personnel involved in and familiar with ablative resurfacing treatments. Patients treated with the long pulse programme presented with oedema and slight exudation the day after resurfacing but reported a mild ache with almost no discomfort. Seven days after Er:YAG fractional resurfacing, scabbing had almost totally disappeared in all 30 patients, with detachment of the crust occurring between days 3 and 4 for the short pulse programme, around day 5 for the medium pulse programme and between days 6 and 7 for the long pulse programme. The intensity of the erythema was directly correlated with the length of the treatment pulse. The new skin was fine and fresh-looking in all cases, and fine lines had disappeared.

Table 3 correlates the subjective assessment of the results achieved at the 2-month assessment point, broken down by both treatment programme and treated area. The majority of patients were treated on the upper lip (19/30), followed by periocular (8/30) and full face resurfacing (3/30). Best results were for the full face and the upper lip compared with periocular resurfacing, although this might have been a function of patient numbers. Table 4 correlates the improvement in lines and wrinkles at the 7-day and

2-month assessments with the original wrinkle grade. Increased improvement in all grades was seen at the final assessment point.

Procedure-related pain is described in Table 5, and the majority of patients found the procedure somewhat painful (20/80), although no patient found the pain unbearable. On the other hand, no patient was totally pain free. Table 5 also shows the degrees of erythema and hyperpigmentation at the 7-day assessment point, which are perhaps difficult for patients to assess because of inter-individual subjective variations. Although none found severe erythema, 12 of the 30 patients felt their erythema was bad at post-treatment day 7, and the remaining graded it as noticeable to mild. No patient was erythema free. Some degree of hyperpigmentation was seen in three patients, with none seen in the remaining 27. Table 6 further shows the evolution of erythema and hyperpigmentation between the two assessment points and among skin types, from which it can be seen that erythema had completely evolved by the final assessment in all skin types. In nearly all patients it had, in fact, evolved by 2 weeks after treatment: camouflage makeup was recommended in the few cases in which it persisted beyond the 2-week mark. Hyperpigmentation spontaneously resolved in all skin types by the 2-month assessment, except for one type IV patient treated with the long pulse programme. No other complication, such as scarring, developed in any of the subjects, but one skin type II patient, treated on the upper lip, developed herpes simplex seen at the 7-day assessment, which was possibly related to the too-early application of camouflage makeup but which had completely resolved by the 2-month assessment. It should be noted here that prophylactic anti-herpes agents were not used at all in this study.

The comparison between the patients' and clinicians' assessments of efficacy can be seen in Table 7, for the 7-day and 2-month assessments. Both clinicians concurred in all assessments. Although the clinicians' assessments tended to be more favourable than the subjective patients' scores, they correlated very well. The one patient who rated herself worse at the 2-month assessment was the long

Table 4 Patients' subjective changes in lines and wrinkles at the 7-day and 2-month assessment points, by wrinkle grade

Condition	7 days after			2 months after		
	Wrinkle grade			Wrinkle grade		
	I	II	III	I	II	III
Lines	+++	++	+	+++	++	++
Wrinkles	+	+	±	+++	+++	++

+++ Very much less, ++ much less, + somewhat less, ± little or no improvement, - worse

Table 5 Degree of procedure-related pain, and erythema and pigmentation (7-day assessment)

Condition	Degree				
	+++	++	+	±	-
Pain	0	8	20	2	0
Erythema	0	12	7	11	0
Pigmentation	0	1	1	1	27

Pain grade: +++, extremely painful (10–9 on the VAS); ++, very painful (7–8); +, bearable (6–4); ±, little pain (1–3); -, no pain (0)
Erythema and pigmentation: +++, severe; ++, bad; +, noticeable; ±, mild; -, none

Table 6 Erythema and hyperpigmentation at the 7-day and 2-month assessments, correlated with patients' skin types

Skin type	Assessment points	Condition	
		Erythema	Hyperpigmentation
II	7-day	+	–
	2-month	–	–
III	7-day	++	–
	2-month	–	–
IV	7-day	++	±
	2-month	–	±

+++; Severe; ++, bad; +, noticeable; ±, mild; —, none

pulse-treated type IV patient in whom hyperpigmentation had persisted. In both the patients' and clinicians' assessments, improved scores were apparent at the final assessment compared with the 7-day assessment, which is in agreement with all previous resurfacing and rejuvenation studies having a longer-term follow-up.

Subjective patient satisfaction grades and numbers 7 days and 2 months after fractional Er:YAG resurfacing are seen in Table 8. The satisfaction indices (SI, calculated by the addition of VS and S values and expressed as a percentage of the patient population) for the 7-day and 2-month assessments were 63.3% and 83.3%, respectively, once again showing an improved SI for the longer follow-up.

Typical histological findings at baseline and at the 2-month assessment are shown in Fig. 1, and typical examples of clinical photographic evidence before treatment and 7 days and 2 months after treatment are illustrative of the results and progression in time of the various degrees of wrinkles treated in Figs. 2 and 3. The patient who contracted herpes simplex is seen in Fig. 4, but the improvement in her wrinkles should also be noted.

Table 7 Subjective (patient) and combined objective (clinician) efficacy scored at the 7-day and 2-month assessments after single-session fractional Er:YAG resurfacing (by numbers of patients)

Scores	Assessments			
	7 days after		2 months after	
	Patient	Doctors	Patient	Doctors
+++	2	6	6	8
++	16	18	18	20
+	12	6	5	2
±	0	0	0	0
–	0	0	1	0

Patient: +++, excellent; ++, good; +, fair; ±, little or no change; –, worse. Doctors: +++, excellent improvement (85–100%); ++, good improvement (60–84%); +, fair improvement (30–59%); ±, little or no improvement (0–29%); –, worse

Table 8 Patient satisfaction grades and numbers at 7 days and 2 months after fractional Er:YAG resurfacing

Score	Assessment point	Number of patients
VS	7 days	4
	2 months	7
S	7 days	15
	2 months	18
SS	7 days	11
	2 months	4
NS	7 days	0
	2 months	1

VS very satisfied; S satisfied; SS fairly satisfied; NS not satisfied. Satisfaction indices for the 7-day and 2-month assessments (SI, calculated by adding the VS and S values expressed as a percentage of the patient population) were 63.3% and 83.3%, respectively.

Discussion

The aim of our carrying out only one treatment and not various sessions of treatment, as is usually recommended in fractional resurfacing, was to meet patient compliance to the maximum and to achieve the best possible skin improvement, while still respecting safety aspects and obtaining rapid tissue recovery. Treatment was not only to improve the appearance of wrinkles, but comprehensively to remove other symptoms of photo-aging, meeting all the criteria of "skin rejuvenation" as proposed by Bitter [2].

To achieve this, our goal was to gain as much of an effect as possible in one treatment but with controlled photothermal reactions, so that patients could rapidly re-incorporate their daily activities. At the same time, in those patients presenting with degree III wrinkles, we sought to leave enough thermal damage with one treatment to subsequently stimulate the underlying dermis, thereby triggering collagen formation through the wound healing process. [3]

The thermal effects of Er:YAG laser can be substantially enhanced when treatment is carried out with sub-ablative energies [4]. As a result of eight passes, in the case of skin presenting with grade III wrinkles in the treatment with the long pulse programme, heat accumulated in the epidermis with repeated passes having a small interpulse interval and reached the underlying dermis in the form of conducted heat. On the other hand, one or two laser passes with fractional Er:YAG laser resurfacing produced a very mild epidermal micro-peel, with minimal or no thermal propagation to the dermis. This was the aim in the treatment of grade I wrinkles with the short pulse programme. When patients presented with grade II wrinkles, the medium pulse programme was used. In principle, when fractional resurfacing with Er:YAG laser is carried out with various combinations of passes, the epidermis can be removed precisely and progressively and the skin takes only a few

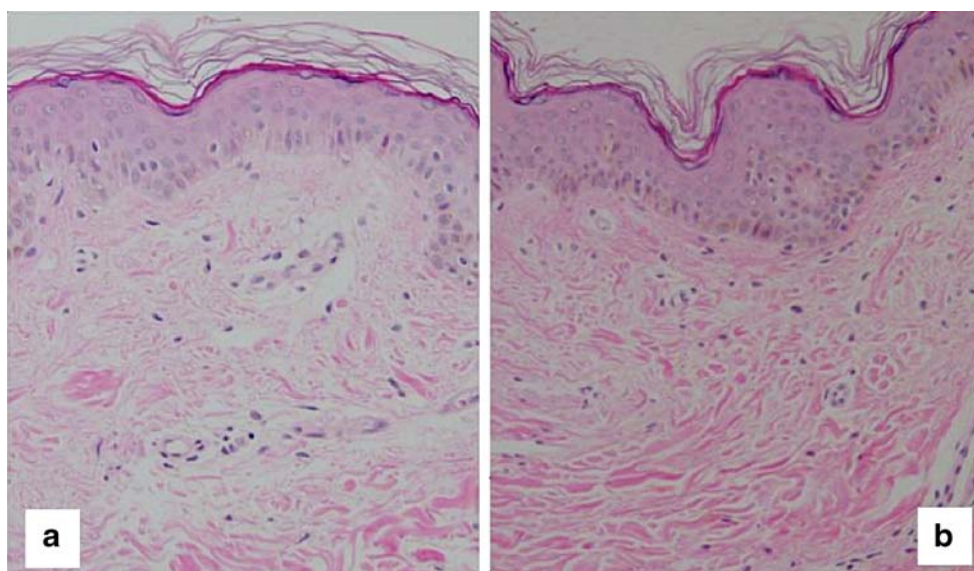


Fig. 1 Skin before (a) and 2 months after (b) a single treatment (1,400 mJ, eight passes). A dense keratin on a typical photo-aged epidermis and dermis. The basal epidermal layer is not well defined, and, in the dermis, there is lack of fibre organization and noticeable interfibrillary spaces typical of the elastosis phenomenon. (b) Two months after, the tissue aspect is more in accordance with a younger

skin, with a multicellular wavy epidermis. The dermo-epidermal junction is well defined, with fine collagen fibres, well organized linearly, in the superficial dermis running parallel and attached to the basement membrane. In general, the collagen fibres are more compact and with fewer interfibrillary spaces. Both H&E, $\times 4$

days to heal. With only a few laser passes, improvement occurs in the “dull” appearance of a photo-aged epidermis but with little repercussion in the dermis because of the low level of conducted heat deposited there. As a result, this will not have any real effect on wrinkles. On the other hand, several Er:YAG passes during fractional resurfacing, with the higher energy of the long pulse programme, will peel the skin more deeply, deposit much more heat into the dermis to give the required residual thermal damage, and will thus bring about beneficial morphological changes to both the epidermis and the superficial dermis due to the

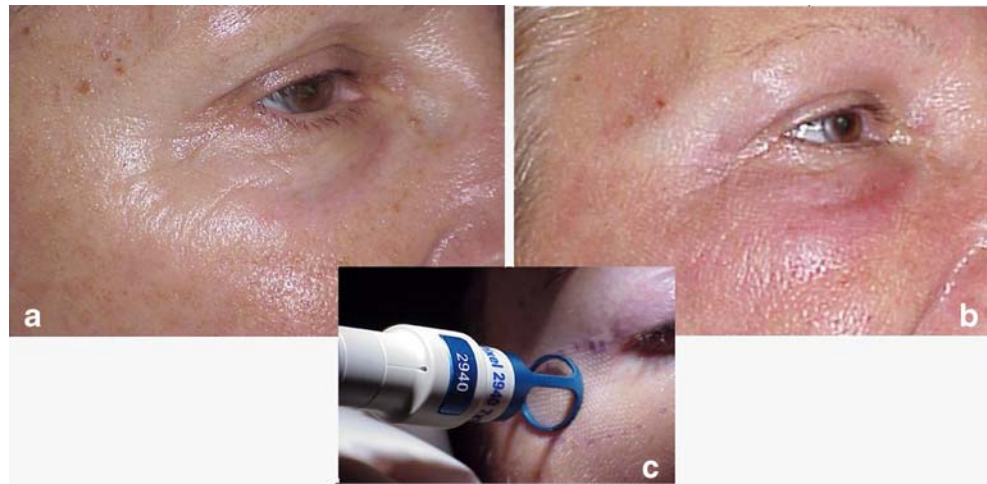
wound healing process brought into play by the thermal damage in the dermis [5].

To achieve the maximum possible effect with only one treatment, we chose the long pulse programme in eight passes to produce better skin results regarding wrinkles. Multiple passes, with the long pulse programme, in only one treatment could be thought of as “more aggressive” than has been previously reported in studies [6,7]. However, we believe that the treatment as described not only changes the aspect of the epidermis but increases the level of photothermal dermal irritation via heat propagation to

Fig. 2 Caucasian woman, 50 years old, phototype III, (a) before and (b) after full-face fractional resurfacing with Er:YAG laser (1,400 mJ, eight passes, only one treatment); details of the periocular area are emphasized in order to show the improvement of wrinkles and skin texture, lightening and rejuvenation of the whole aspect of the skin. c The patient during treatment

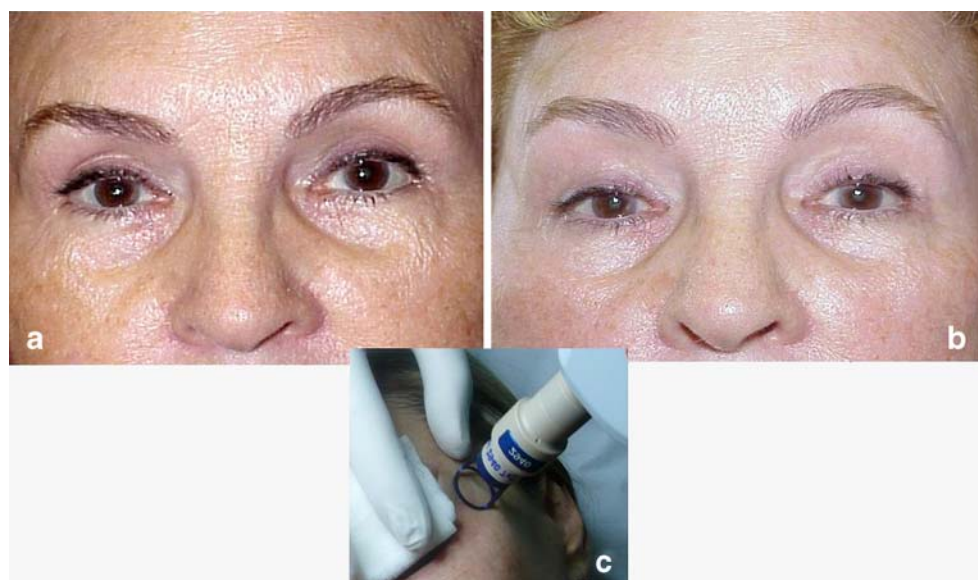

Fig. 3 Caucasian woman, 52 years old, skin phototype IV, (a) before and (b) after periocular resurfacing (1,400 mJ, eight passes, one treatment). Observe the better skin condition and fewer wrinkles at the 2-month assessment point. c During treatment

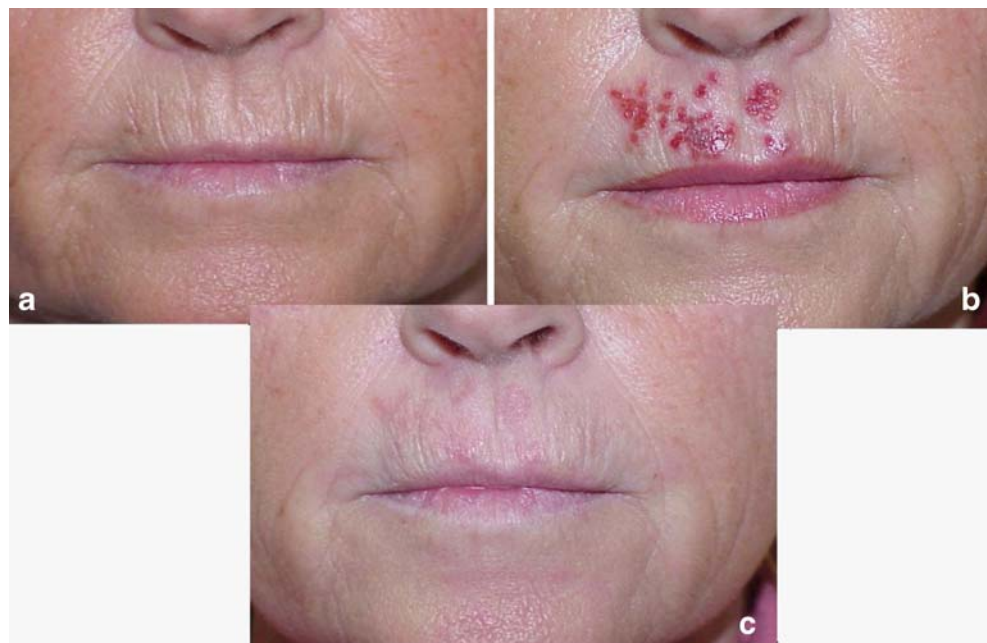

affect the dermis. The primary action achieved by the Er:YAG resurfacing treatment is epidermis renewal, but the stacking of passes deposits sufficient heat in the dermis to stimulate neocollagenesis, which is essential to provide the result both the clinician and patient require, because the architecture of both the epidermis and the dermis is improved. In fact, the external aspect of the skin, namely the epidermis, is what patients first see when looking in the mirror, and beneficial changes in the epidermis can be achieved in grade I wrinkles with one or two passes with the fractional Er:YAG laser and the short pulse programme, with little thermal damage in the dermis accelerating the repair process. The medium pulse programme with more passes is required for more noticeable grade II wrinkles, to deposit more heat into the dermis and start neocollagenesis. For much more established grade III wrinkles, however, the

long pulse is required, with a larger number of passes, so that the resurfaced epidermis has the “younger” appearance essential in skin rejuvenation, but it is accompanied by a significant improvement in the appearance of wrinkles due to good reorganization and tightening of the extracellular matrix. Grade III patients must, therefore, be more prepared to “suffer” a little longer from the more intense side effects of the treatment rather than not resolve the problem of the wrinkles. Patient education is, therefore, extremely important to manage realistic patient expectations.

Fractional resurfacing with Er:YAG laser with low incident doses and few passes for wrinkle treatment will obviously require more than one treatment session to enhance the condition of moderate to severely photo-aged skin. However, each subsequent treatment session at the same parameters will not go any further than the previous

Fig. 4 Caucasian woman, 48 years old, skin phototype II, (a) before and (b) 1 week after fractional resurfacing of the upper lip. Tissue has healed after skin ablation, with clear improvement of the wrinkles; however, clear signs of herpes simplex infection are observed. c Aspect at 2 months after treatment. Herpetic lesion has healed without any scarring, but some lesion-related residual erythema is still present. Wrinkles are significantly better



session and will fail to trigger the essential dermal wound healing processes, which are absolutely essential to achieve a better in-depth skin condition and for the elimination of lines and wrinkles. In contrast, as seen in this study, with only one treatment at high energies and multiple passes, the results were evident even in grade III wrinkles. One particularly interesting advantage is that, although the dermis is affected and the epidermis eliminated, tissue healing is achieved quite quickly. From 5 to 7 days after one single treatment, the skin was free of fine scabs and had a rejuvenated aspect with minimized erythema. This is easy to mask with cosmetics, and patients are ready to return to their business or social life in a very short time.

Interviews with patients have shown that compliance with a laser resurfacing protocol is better when only a single treatment is carried out. Moreover, the increased SI 2 months after treatment in patients treated with the higher energy density of the long pulse programme and eight passes matched the expected results better.

Previous observations extracted from patients treated by us with the same device (data not published) and a number of treatment sessions with a more conservative pulse programme and fewer laser passes did not show better results than those achieved with only one treatment with the technique described above. In our experience, often when patients are interviewed before treatment, they do not wish to undergo various sessions of treatment, and, even when they agree to a multiple treatment regimen, compliance with the protocol can be less than perfect. The feasibility and efficacy of our treatment protocol are justified by the fact that no patient reported any complications and that all completed both the assessment points.

Clinical improvements obtained with non-ablative lasers are, in general, modest at best [8]. So far, devices for skin rejuvenation associated with the use of all types of non-ablative rejuvenation treatments provide excellent dermal histology and good collagen remodelling. However, these achievements are not always echoed in enough epidermal rejuvenation and patient satisfaction [9–12], and, moreover, the long treatment regimens associated with non-ablative methods also cause problems with patient compliance.

In this study, the results were satisfactory in all those patients presenting with grade I and grade II wrinkles, treated in one session with the short and long pulse programme, respectively, but degree II wrinkles appeared to benefit less from the medium pulse programme. This could be because degree II wrinkles correspond to an intermediate phase of dermal tissue deterioration, and visual diagnosis fails to be totally accurate. Clinicians should be aware that, when examining patients for wrinkle diagnosis and allocation of pulse programme treatment, patients should be asked to accentuate a range of facial expressions,

such as frowning, looking surprised, laughing, looking angry, and so on. In this way, wrinkles and lines not obviously apparent can be seen, thus helping the clinician to determine the true aspect of the wrinkles on a patient-by-patient basis.

Our study showed that pain was not a major problem during treatment, and there were no side effects. The absence of complications, except in the one patient who presented with hyperpigmentation, can be used as an argument to recommend a second session of treatment for those patients whose expectations have not been met. Once again, the importance of managing realistic patient expectations is clear. “Top-up” sessions at subsequent intervals will also thus be well-accepted.

The fractional ablative Er:YAG laser device used in this study has other possible applications in various skin disorders and aesthetic conditions, in relation to ageing and cicatricial pathologies. The combination of fractional resurfacing with, for example, an IR wavelength hand-piece, used before ablative fractional resurfacing with the Er:YAG hand-piece, can heat the dermis, possibly adding extra value to improve the final results. The instigation of an appropriate adjunctive regimen of epidermal care might also help improve results even more, [13], as might adjunctive phototherapy with light-emitting diodes (LEDs) of appropriate wavelengths.

The histological findings 2 months after treatment showed a better collagen appearance, more evident in those patients treated with high energy levels and multiple passes. Improvement in the dermal architecture and organization seen in the histology 2 months after treatment were very well correlated with the better external gross aspect of the area treated, which was clearly the reason behind the high SI of 83% as reported by patients at the 2-month assessment point.

Conclusions

Fractional resurfacing with Er:YAG laser in only one treatment session can achieve effective skin rejuvenation, with effects on both the epidermis and dermis. If the treatment programme chosen is the long pulse mode, at 1,400 mJ total energy per pulse, and eight passes are carried out, the results obtained, as illustrated in our study, can be highly efficacious and can be clinically and histologically demonstrated. The treatment programme can be accurately correlated, according to the degree of the signs of photoaged skin intended for rejuvenation. No complications were noted, except for one case of slight hyperpigmentation in a woman with phototype IV skin. Side effects, such as pain, discomfort, fine scabbing, oedema and erythema, are well tolerated and accepted by patients. The side effects can

be very well controlled, so, if necessary, extra treatment sessions can be carried out.

Acknowledgements The authors declare no financial or other interest in the companies and/or equipment mentioned in this study. The report given in this study is registered in the academic activities of the Fundacion Antoni de Gimbernat, 2006–2007.

References

1. Gold MH (2007) Fractional technology: a review and clinical approaches. *J Drugs Dermatol* 6:849–852
2. Bitter PH (2000) Noninvasive rejuvenation of photoaged skin using serial full-face intense pulsed light treatments. *Dermatol Surg* 26:835–843
3. Trelles MA, Mordon S, Benítez V, Levy JL (2001) Er:YAG laser resurfacing using combined ablation and coagulation modes. *Dermatol Surg* 27:727–734
4. Miller LD (1997) The erbium laser gains a role in cosmetic surgery. *Biophoton Int* May/June 38–42
5. Trelles MA (2007) Red light-emitting diode (LED) therapy assisted healing improves results of facial skin fractional resurfacing. 16th European Academy of Dermatology and Venereology Congress, 16–20 May 2007, Vienna, Austria
6. Lee MW (2002) Combination visible and infrared lasers for skin rejuvenation. *Semin Cutan Med Surg* 21:288–300
7. Lee MW (2003) Combination 532-nm and 1064-nm lasers for noninvasive rejuvenation and toning. *Arch Dermatol* 139:1265–1276
8. Tanzi EL, Williams CM, Alster TS (2003) Treatment of facial rhytides with a nonablative 1,450-nm diode laser: a controlled and histologic study. *Dermatol Surg* 29:124–128
9. Menaker GM, Wrone DA, Williams RM, Moy RL (1999) Treatment of facial rhytides with a nonablative laser: a clinical and histological study. *Dermatol Surg* 25:440–444
10. Goldberg DJ (1999) Non-ablative subsurface remodeling: clinical and histological evaluation of a 1320 nm Nd:YAG laser. *J Cutan Laser Ther* 1:153–157
11. Goldberg DJ (2000) Full-face nonablative dermal remodeling with a 1320 nm Nd:YAG laser. *Dermatol Surg* 26:915–918
12. Trelles MA, Allones I, Luna R (2001) Facial rejuvenation with a nonablative 1320 nm Nd:YAG laser: a preliminary clinical and histological evaluation. *Dermatol Surg* 27:111–116
13. Trelles MA, Allones I, Velez M (2003) Nonablative facial skin photorejuvenation with an intense pulsed light system and adjunctive epidermal care. *Lasers Med Sci* 18:104–111